



Imaging Redefined

# VITAL

# IMAGING Newsletter

## State-Of-The-Art Imaging in Gastroenterology

### VITAL IMAGING Gastroenterology Case Studies

#### Imaging Redefined

- MULTISLICE SPIRAL CT SCAN
- ✓ TRIPLE PHASE CT
- ✓ VIRTUAL COLONOSCOPY
- DIGITAL IVP
- DENTAL CT
- DIGITAL OPG
- PORTABLE DIGITAL X-RAY
- SONOGRAPHY
- COLOR DOPPLER
- PATHOLOGY

#### VITAL IMAGING CENTRE

B – ROYAL CLASSIC,  
New Link Road, Next To  
Fame Adlabs, Andheri -W,  
Mumbai – 53.

PH: 2630 1184 / 85

Email:

[vitalimaging@yahoo.com](mailto:vitalimaging@yahoo.com)

8:30A.M. – 8:30P.M.

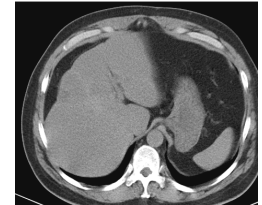
**24 X 7  
EMERGENCY  
SERVICE  
AVAILABLE**

### Interesting Case Studies:

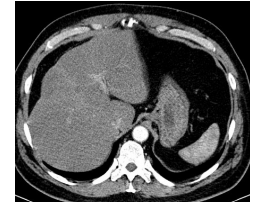
#### Case Study 1: Role of Triple Phase Liver Imaging

45yr old asymptomatic patient went for a routine health check and the USG revealed a focal lesion in the liver labeled as focal fat deposition. The patient underwent a repeat USG and the same findings were mentioned.

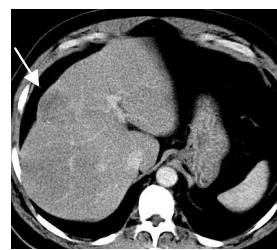
The patient subsequently underwent a **Triple Phase Liver Imaging** at VITAL. A 4.5 X 4 cms sized ill-defined lesion with subtle enhancement is seen in segment VIII of liver, the lesion was much better appreciated on venous and delayed phase images. A CT diagnosis of malignant lesion was made further confirmed as cholangiocarcinoma on histopathology and surgery.



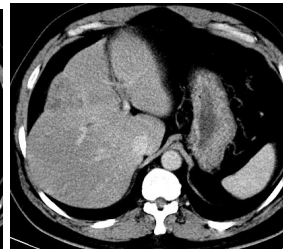
Non-Enhanced Phase



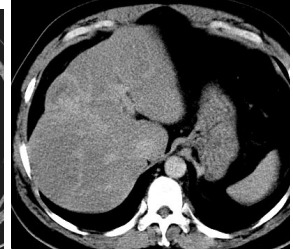
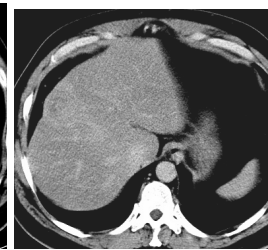
Arterial Phase



Venous Phase



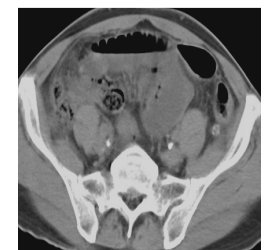Delayed Phase



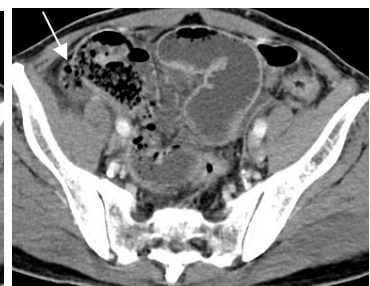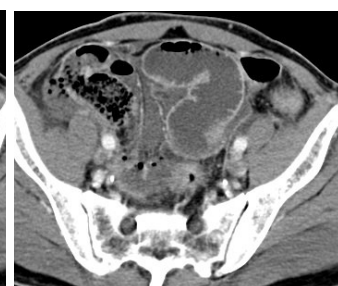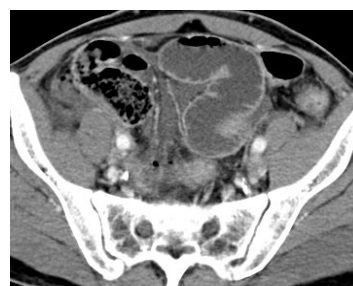#### Case Study 2: Role of Emergency CT in GIT

60 yr old man with h/o blunt abdominal trauma in the mid abdomen. Patient developed abdominal pain and underwent a USG Abdomen & Digital X-ray Abdomen Erect and revealed no significant abnormality. The surgeon asked for an Urgent CT Abdomen.

An **Urgent Contrast Enhanced CT Abdomen** was performed at VITAL. There was a small bowel (ileal) perforation visualized in the right iliac fossa region with localized free air pockets, no free fluid was noted. A reliable diagnosis of small bowel perforation was obtained with the availability of Urgent CT Scan inspite of no obvious findings on USG and X-ray. The findings were confirmed on surgery.



Plain Axial Image



Contrast Enhanced Axial Images

For more information, or for any questions, concerns or suggestions please do call us on  
Ph: 2630 1184 / 85.

(For Private Circulation Only)

VITAL IMAGING >>> EXCELLENCE IN IMAGING .... ALWAYS!